


PRESENTING CLINICAL SIGNS

History: Becoming more lethargic and less mobile over the past month. Radiographs revealed cranial mediastinal widening with tracheal deviation. CT showed no definitive evidence of a mass.

DATE

12/20/22

ECHOCARDIOGRAPHIC FINDINGS

2D, M-mode, and Doppler study.

PERFORMED BY:

Tom McNeill

Left atrial size is normal. The mitral valve is normal. Left ventricular dimensions are normal. Left ventricular systolic function is normal. The aorta and aortic valve are normal. Right atrial and right ventricular dimensions are normal. The tricuspid valve is normal. The pulmonary artery and pulmonic valve are normal. No shunting lesions are visualized. No pericardial effusion or cardiac masses are seen.

INTERPRETED BY

 Keith Blass, DVM,
 MS, DACVIM
 (Cardiology)

 LA - 21.8 mm
 LVIDd - 21.9 mm
 LVIDs - 14.5 mm
 FS - 33.8%
 RA - 17.3 mm
 LVOT - 1.53 m/s
 RVOT - 1.16 m/s

PATIENT

Cali Beckett

ASSESSMENT/RECOMMENDATIONS
SPECIES

Canine

Normal echocardiogram

This examination demonstrates no evidence of structural heart disease. While echocardiography cannot definitively rule out the presence of a cardiac neoplasm, one was not seen in the image set, and the absence of a mass in Cali's CT scan suggests that one is unlikely to be present.

BREED

Pug

No cardiac therapy is recommended based on this exam.

A recheck echocardiogram is recommended if new physical exam and/or clinical abnormalities compatible with cardiac dysfunction develop.

SEX

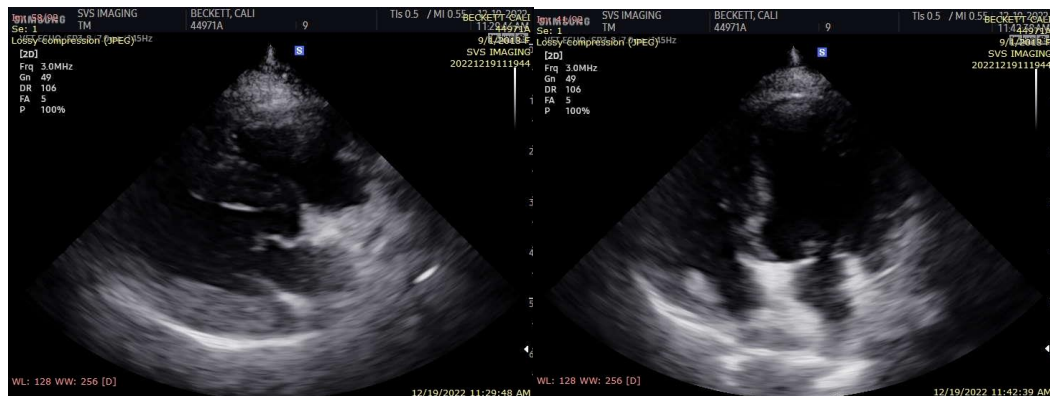
FS

AGE

9 y

WEIGHT

6.2 kg


HOSPITAL NAME

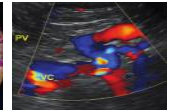
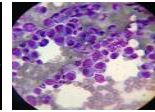
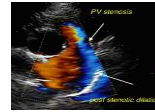
SVS Imaging CT

The information and recommendations provided are based on the images presented by the referring veterinarian. No evaluation can be communicated regarding pathology that was not visible in the image/video clips provided.

REFERRING VET

Dr. McDaniel

Thank you for this referral. If the clinical or image interpretation does not parallel your findings or



if I can be of any further assistance please contact me.

DATE

12/20/22

Keith Blass, DVM, MS, DACVIM (Cardiology)

KeithBlass@gmail.com

631-804-5754

PERFORMED BY:

Tom McNeill

INTERPRETED BY

Keith Blass, DVM,

MS, DACVIM

(Cardiology)

PATIENT

Cali Beckett

SPECIES

Canine

BREED

Pug

SEX

FS

AGE

9 y

WEIGHT

6.2 kg

HOSPITAL NAME

SVS Imaging CT

REFERRING VET

Dr. McDaniel